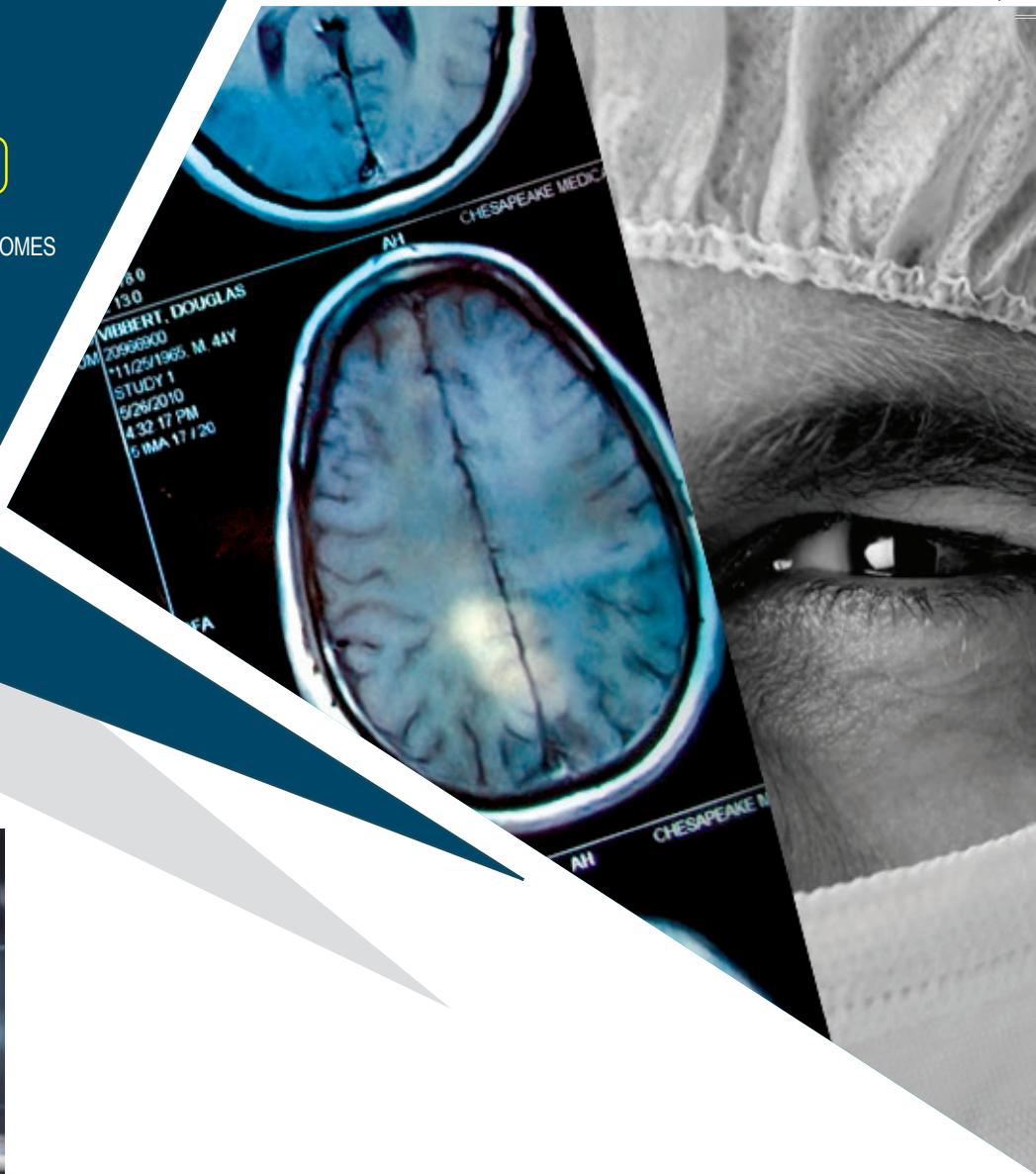

clinical experience

THE SCIENCE BEHIND POSITIVE PATIENT OUTCOMES



Dr Vipul Gupta, MD

Dr Vipul Gupta is Director and Head of department of Neurointerventional Surgery (Interventional Neuroradiology) and co-director comprehensive stroke care unit at Artemis Hospitals. Prior to joining Artemis, he was head of Neurointervention Unit at Medanta the Medicity.

He trained in Interventional Neuroradiology at All India Institute of medical Sciences (AIIMS) and was Associate Professor in dept. of Neuroradiology (AIIMS).

Introduction

Stroke is the third most common cause of death worldwide after ischemic heart disease and cancer. Approximately 30% of patients die within the first year of having a stroke and another 50% are left disabled. About 15% of strokes are preceded by transient ischaemic attacks (TIA) and timely appropriate treatment can avoid major stroke in these patients. Extracranial atherosclerotic disease accounts for up to 15% to 20% of all ischemic strokes. With availability of revascularization techniques such as carotid endarterectomy and carotid stenting, the risk of stroke can be reduced substantially.

There is robust evidence in favor of carotid revascularization in patients with symptomatic stenosis with a relative risk reduction of a further stroke by 65% (c.f- RRR of 15% with Ecosprin).

CASE 1

Carotid Stenosis- The Art of Management!

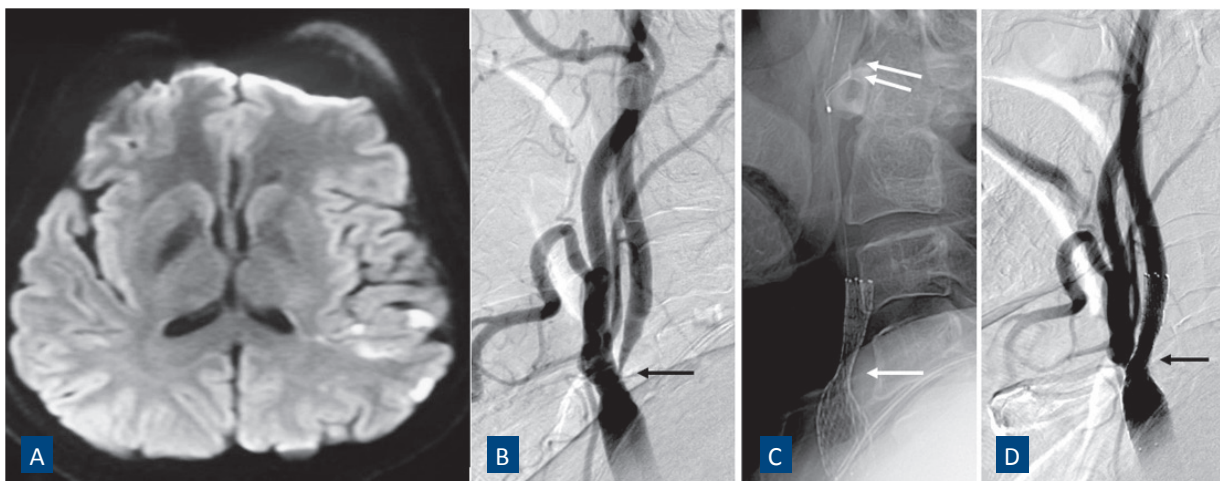


Figure 1: 52-year old male presented with transient loss of speech. A - MRI diffusion weighted image showing small foci of infarction in left temporal region. B- Carotid angiography revealing severe stenosis at origin of left internal carotid artery (arrow). Patient was at high risk of stroke. C- Carotid stent placement (arrow, C) was performed with help of protection device (double arrow). D – Final angiogram showing well open carotid artery.

Key points

- Carotid artery stenosis is frequently associated with minor stroke and TIA (in approximately 20-25% of cases).
- Carotid stenting is advised if symptomatic stenosis on CT/MR angiography is >70% (>50% on DSA) because recurrent stroke can happen inspite of medical therapy.
- Carotid artery stenting is done via transfemoral route under local anaesthesia.
- Relative risk reduction of further stroke: 65%.
- Absolute risk reduction of 17% with a Number needed to treat to benefit of 6.
- Use of filter or protection device is recommended in cases of carotid stenting.
- Early intervention is helpful as TIA leads to major or minor stroke. (For details, kindly look at the risk assessment chart).

Indications for Revascularization

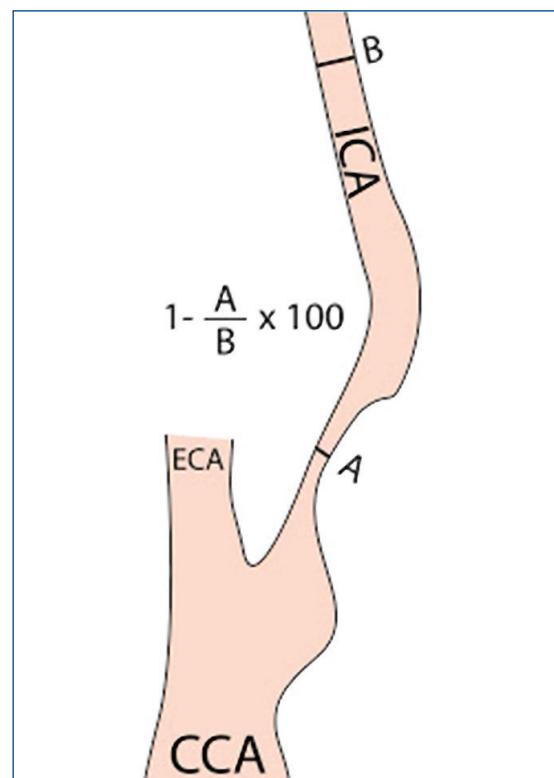
Symptomatic stenosis

- CEA or CAS are indicated for symptomatic patients when the diameter of the lumen of the internal carotid artery is reduced by >70% by noninvasive imaging or >50% by catheter-based imaging or noninvasive imaging with corroboration and the anticipated rate of periprocedural stroke or death is <6%.

Asymptomatic stenosis

- As per the recommendations, prophylactic CEA/CAS might be considered in highly selected patients with asymptomatic carotid stenosis (minimum 60% by angiography, 70% by validated Doppler ultrasound), but its effectiveness compared with medical therapy alone in this situation is not well established. We aim to define the patient group with high risk of a future stroke. Cerebral reserve can be assessed by transcranial doppler study. We prefer to consider an asymptomatic patient for revascularization when the stenosis is more than 80%, cerebral reserve is impaired and the case is not considered to have a high risk of peri-procedural complications.

NASCET Criteria for Carotid Stenosis



The North American Symptomatic Carotid Endarterectomy Trial (NASCET) is a method of quantifying internal carotid artery stenosis.

The diameter of the stenotic segment(A) is divided by the diameter of a normal, distal segment of internal carotid artery(B) (where walls are parallel) and subtracted from 1.

CASE 2

Carotid stenosis causing Crescendo Transient ischemic attacks(TIA's)

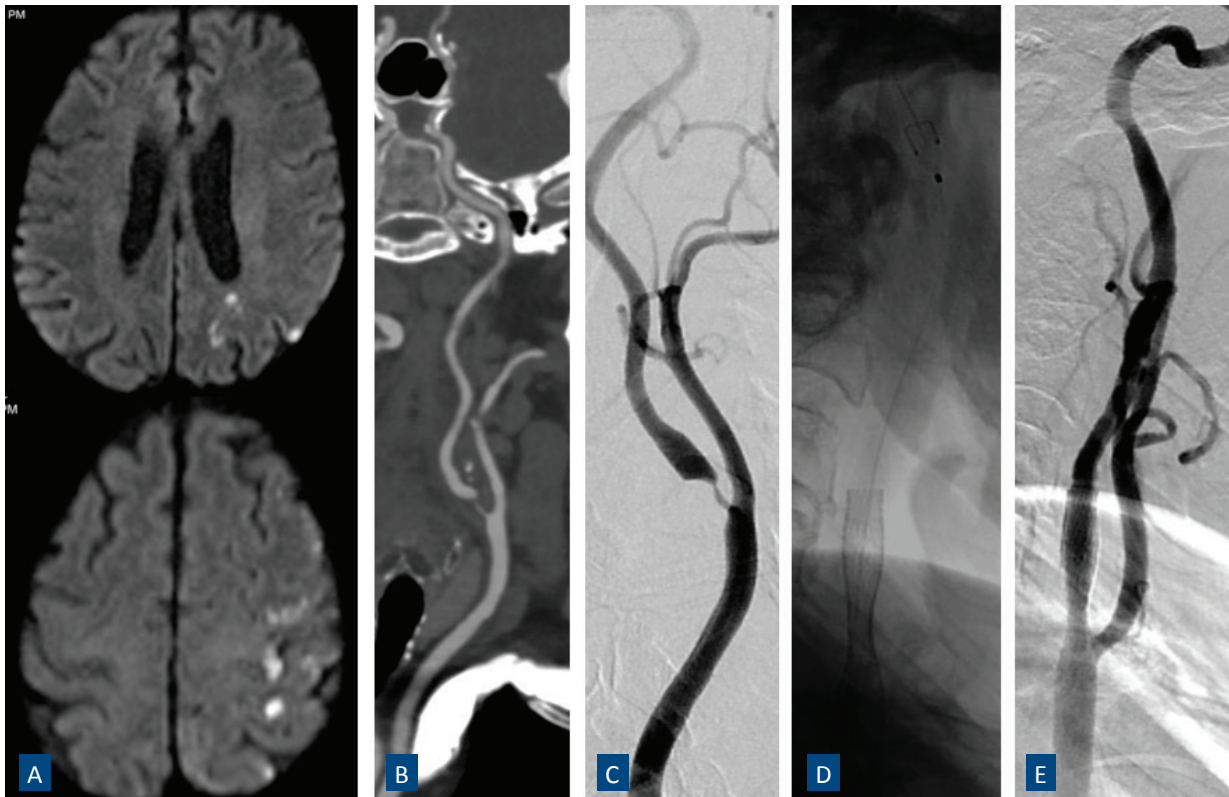


Figure 2: 76-year old female presented with multiple episodes of recurring left sided weakness, increasing in severity. A - MRI diffusion weighted image showing small foci of infarction in left parietal & frontal lobes. B- CT angiography and C- Carotid angiography revealing severe stenosis at origin of left internal carotid artery (arrow). Patient was at high risk of major stroke. D- Carotid stent placement (arrow, D) was performed with help of protection device (double arrow). E – Final angiogram showing well open carotid artery.

Key points

- Crescendo TIA's will need urgent treatment as chances of developing a major stroke is high. (Please note that risk is nearly doubled .For more details, kindly look at the risk assessment chart)
- Emergency carotid stenting can be done.

Urgency of Treatment

- Once a TIA is clinically diagnosed, carotid imaging should be performed immediately, and if indicated, patients should be referred for urgent carotid revascularization (carotid endarterectomy or stenting). Two major randomized trials have confirmed that symptomatic patients benefit from revascularization procedures.
- **Risk of stroke following a TIA is 5.5% at 48 hours, 8.0% to 10.3% at 7 days, 11.5% to 14.3% at 30 days, and 17.3% to 20.1% at 90 days (level II).**

Carotid Artery Stenosis Causing Major Stroke

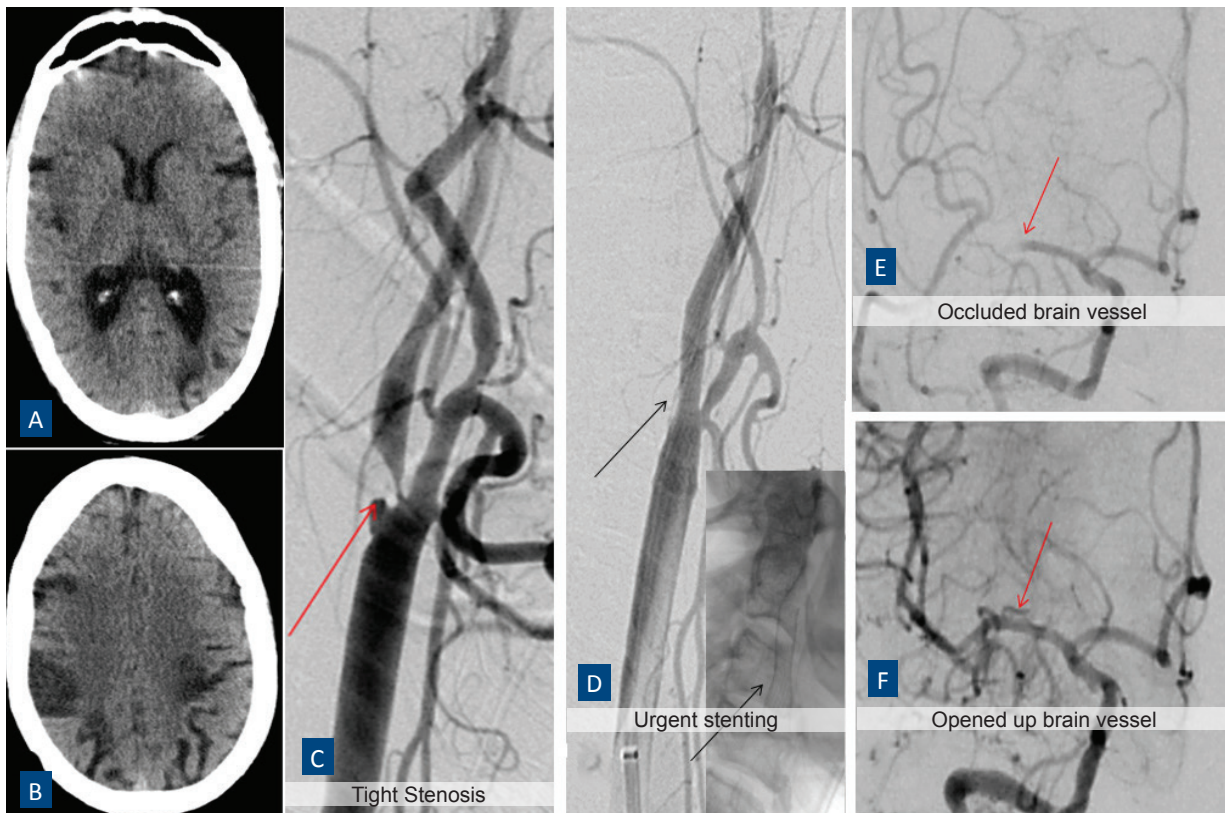


Figure 3: 56-year old male presented with TIA of left arm weakness. 2 months prior to stroke he was evaluated and diagnosed with right ICA stenosis. He declined stenting treatment. He presented to emergency with complete left sided weakness and NIHSS of 14. A & B– CT showed old chronic infarcts in the right MCA territory. C- Carotid angiography revealing severe stenosis at origin of right internal carotid artery (arrow). D- Carotid stent placement (inset)(arrow, D) was performed with help of protection device (double arrow). E – The right MCA was occluded. F- Right MCA was opened up using Penumbra device. Patient made good clinical recovery.

Key points

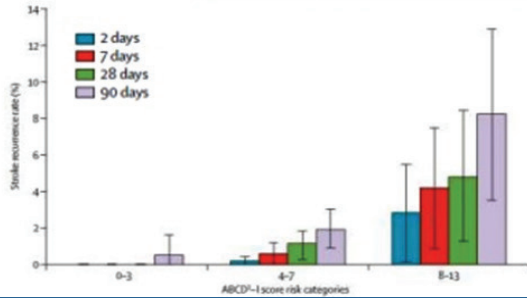
- In cases of hyperacute stroke (<6 hours duration) associated with carotid stenosis, emergency carotid stenting with mechanical thrombectomy, to remove the intracranial occlusion, should be performed.
- These procedures are done to reverse stroke unlike elective CAS which is done to prevent further TIA/stroke.
- Published ASA/AHA guidelines recommend mechanical thrombectomy in major stroke due to occlusion of ICA and MCA but the procedure has to be started within 6 hours of stroke.
- Many patients with ICA occlusion may have underlying ICA stenosis which may require stenting or sometimes only carotid angioplasty can be done which can later be followed by stenting.

Risk of Stroke after Tia

Risk stratification for TIA with ABCD³-I score

Table 1: ABCD³-I

Clinical Feature	ABCD ³ -I Points
Age \geq 60 years	1
BP Systolic $>$ 139 or Diastolic $>$ 89 mm Hg	1
Speech Impairment without weakness	1
Unilateral Weakness	2
Duration \leq 59 minutes	1
Duration $>$ 59 minutes	2
Diabetes present	1
Dual TIA (Second TIA within 7 days)	2
Same sided $>$ 49% stenosis of ICA	2
MRI showing hyperintensity on Diffusion Weighted Images	2
Total Range	0-13



Score	Risk for stroke	Recurrence within 90days
0-3	Low	2-3%
4-7	Intermediate	<6%
8-13	High	>18%

Lancet Neurol 2010;9:1060-69.

Key point

- Risk of stroke is highest in Diabetic, hypertensive patients with two or more TIA's, DWI positive lesion or $>$ 50% carotid stenosis.

Carotid Stenosis with Clot

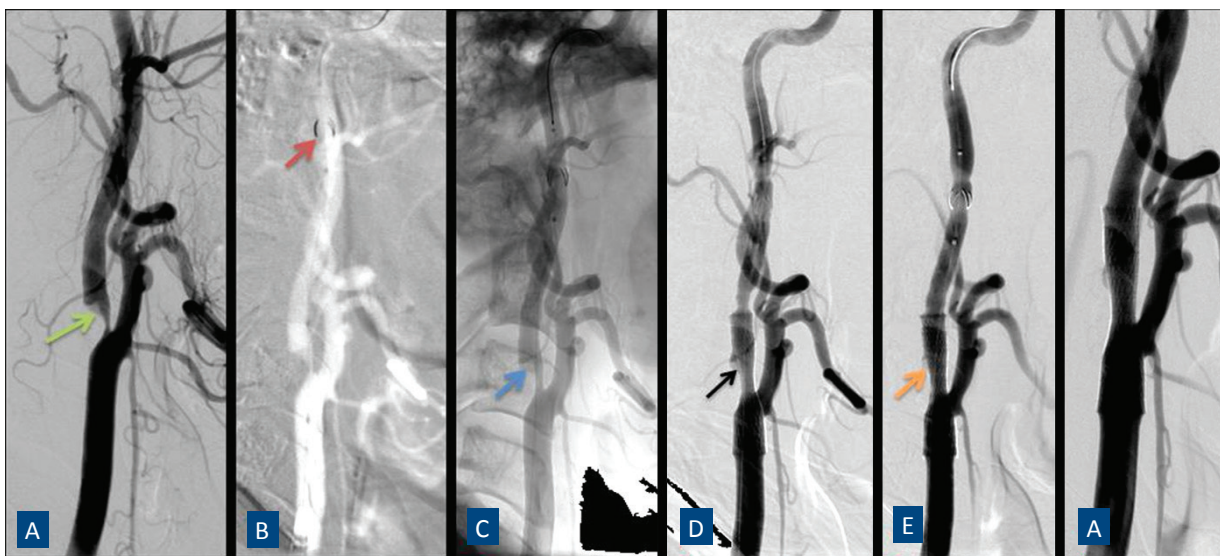


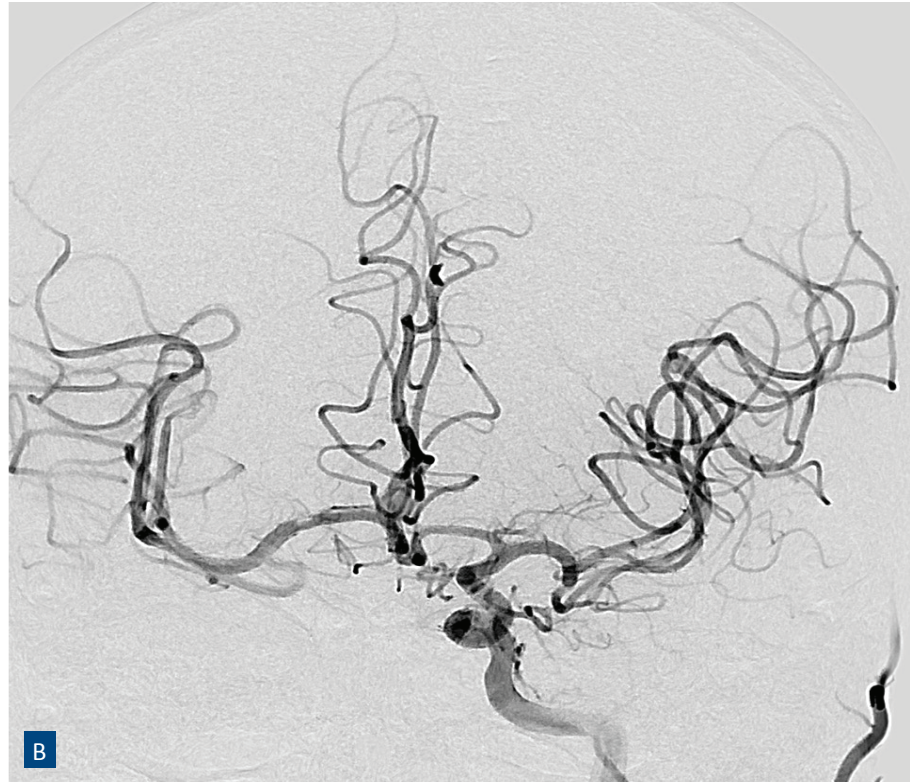
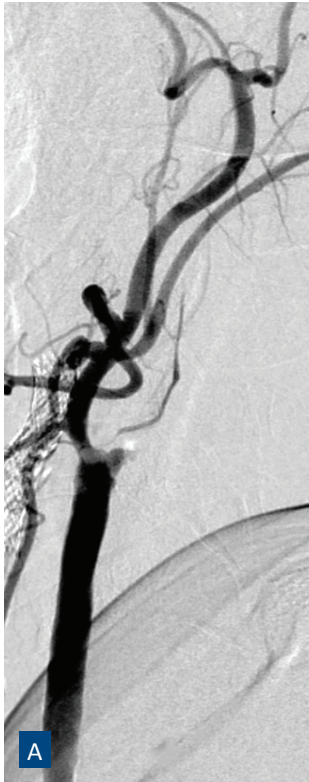Figure 4: 58-year old male presented with TIA of left arm weakness. A- Carotid angiography revealing severe stenosis at origin of right internal carotid artery with a intraluminal clot. (B) The filter was taken across the stenosis, taking care that it does not disturb the clot. (C) A small balloon 3.00 mm X 20 mm was used to do a gentle pre-angioplasty. The clot persists. (Blue arrow). (D) Closed stent Xact 6-8mm x 30 mm was deployed. Post stenting, the clot is squeezed between the wall and stent. (Black arrow). (E) Post stenting angioplasty to completely open the stent and further squeeze the clot. (arrow). F- Final opening of the stenosis and clot is squeezed.

Key points

- In cases of carotid stenosis with intraluminal central clot we have to wait for the clot to resolve.
- Patient has to be on anticoagulants/antiplatelets.
- In selected cases, if needed, and, if the clot is eccentric, a careful carotid stenting should be done along with distal protection device.

CASE 5

When Not to Do? Complete ICA Occlusion on Angiography



Key points

- No intervention should be done in complete ICA occlusion.
- But complete occlusion should be demonstrated on either DSA, CTA or contrast enhanced MRA.
- Doppler and TOF MRA are not completely reliable.
- Good collaterals should be there.



Medical Management

- These patient needs strict control of diabetes and lipids.
- Insulin is a better choice for stricter diabetes control in the setting of an acute stroke. One should target fasting blood sugar <110 mg/dl, post-prandial blood sugar <140 mg/dl and HbA1C of 6.5.
- High dose statins have been shown to stabilize plaques in the coronary circulation. It holds true for extra/intracranial large vessel disease as well. Hence we loaded these patient with 40- 80 mg of Atorvastatin depending on the BMI.

Blood pressure control

- With regards to BP, the data comes from SCAST (Angiotensin receptor blocker candesartan for the treatment of acute stroke) trial. 2029 patients were randomly allocated candesartan vs placebo and followed up for 6 months. Two co-primary end points were composite of vascular death/MI/stroke and functional outcome (mRS) at 6 months. At 6 months, composite vascular end point did not differ between two groups (candesartan 120 events vs placebo 111 events, adjusted HR 1.09, p=0.52). Analysis of functional outcome suggested higher risk of poor functional outcome in the candesartan group (OR 1.17, p=0.04).
- Based on this data, BP should be gradually reduced over a period of 01 week in the setting of an acute stroke.

Single or dual anti-platelets

- CHANCE (Clopidogrel plus Aspirin in acute minor stroke and TIA) trial was conducted in 114 centers in China. 5170 patients were recruited within 24 hours of minor ischemic stroke or high risk TIA. They were randomly assigned to ASA + placebo for 90 days vs ASA + Clopidogrel for 21 days followed by Clopidogrel till 90 days. Primary outcome was stroke (ischemic or hemorrhagic) at 90 day follow up. Stroke occurred in 8.2% patients in ASA + Clopidogrel group vs 11.7% in ASA group (hazard ratio 0.68, p<0.001). Moderate to severe hemorrhage occurred in 0.3% in each group.
- It was concluded that in patients with minor stroke/ TIA who can be treated within 24 hours, ASA + Clopidogrel is superior than ASA alone in reducing the risk of stroke over 90 day period and does not increase the risk of hemorrhage.
- Therefore double antiplatelet therapy is recommended.
- Please note anti-coagulants are not routinely recommended.

Timing of Stenting

- In cases of TIA with no infarct: Immediately
- In cases of Stroke with infarcts: Revascularization should be attempted after 7-10 days of an acute infarct which allows stabilization of infarct and reduces the chances of reperfusion injury.
- The maximum benefit of revascularization is achieved if it is performed within 4- weeks in men and within 2-weeks in women.

CAS Vs CEA

- The most compelling data comes from the recent CREST (Stenting vs Endarterectomy for treatment of Carotid-Artery stenosis) trial.
- This trial recruited patients with symptomatic or asymptomatic carotid stenosis. Symptomatic stenosis was defined as history of TIA or stroke within 06 months with >70% stenosis on CT angiography/MR angiography/ Carotid Doppler or >50% stenosis on digital subtraction angiography (DSA).
- Total of 2502 patients were recruited to either CAS or CEA.
- During the periprocedural period (30 days), there was no difference in ipsilateral stroke/myocardial infarction/ death between two groups.
- Post-procedural risk of ipsilateral stroke was equally low in both the groups when patients were followed upto 04 years (2% in CAS vs 2.3% in CEA).
- Overall, the primary end point of ipsilateral stroke and periprocedural stroke/MI/death was similar in two groups without any statistically significant difference.
- Cranial nerve palsies were seen in 4.7% of CEA patients.
- It was also seen that CAS was a better option for those < 70 years while CEA a better option for those > 70 years (probably related to tortuous and calcified vasculature).
- The decision to opt for either of these revascularization procedures needs to be individualized.
- It is also seen that risk of carotid stenting is least if done by neurointerventionist instead of vascular surgeon or cardiologist.

Key points

- Patients with TIAs have significant risk of stroke particularly with in first few weeks. They should be investigated with urgency
- Patients with hemispheric symptoms, infarct on DWI imaging and major vessel stenosis or occlusion have higher risk of stroke. One should do risk stratification and treat accordingly
- Carotid endarterectomy or carotid stenting are indicated for symptomatic patients when the diameter of the lumen of the internal carotid artery is reduced by >70% by noninvasive imaging or >50% by catheter-based imaging or noninvasive imaging with corroboration and the anticipated rate of periprocedural stroke or death is <6%
- The revascularization procedures should be performed soon (with in 2-weeks or earlier) after the symptoms.
- Both endarterectomy and stenting are reasonable options for revascularization, with low complication rate when performed by trained and experienced physicians.

ARTEMIS NEUROINTERVENTION TEAM



Dr Vipul Gupta
Director and Head
Neurointerventional Surgery



Dr Rajsrinivas Parthasarathy
Consultant Stroke Neurology and
Neurointerventional Surgery



Dr Tariq Matin
Senior Consultant
Neurointerventional Surgery


ARTEMIS NEUROSCIENCES TEAM



Dr Sumit Singh
Director and Head Neurology
& team



Dr Aditya Gupta
Director and Head Neurosurgery
& team



Dr Saurabh Anand & Team
Neuro Anesthesia & Critical Care

Disclaimer: Although great care has been taken in compiling and checking the information given herein to ensure that it is accurate, the publisher shall not be in no way directly or indirectly responsible for any error, omissions or inaccuracy in this publication whether arising from negligence or otherwise. IJCP Publications Ltd. does not guarantee, directly or indirectly, the quality or efficacy of the product or service described in the advertisements or other material which is commercial in nature in this publication.

